

## CELIACOMESENTERIC TRUNK: AN UNUSUAL VARIATION

GARIMA SEHGAL,\* A.K.SRIVASTAVA,\* P.K.SHARMA,\*  
ARCHANA RANI,\* R.K.DEEWAN,\* PALLAVI AGA\*\*, ANIT PARIHAR.\*\*

Department of Anatomy,

\*\*Department of Radiodiagnosis,

King George's Medical University, UP, Lucknow.

### INTRODUCTION

The Abdominal aorta and its major branches supply oxygenated blood to nearly all the organs in the abdominal cavity. Arterial variations in the abdominal region are important during laparoscopic and various other surgical procedures. Abdominal aorta begins in front of inferior border of the twelfth thoracic vertebra at the level of median aortic hiatus of the diaphragm. It descends anterior to the lumbar vertebrae and usually ends at the lower border of the fourth lumbar vertebra a little to the left of the midline, by dividing into its terminal branches which are the two common iliac arteries. The branches of the aorta are subdivided into anterior, lateral and dorsal group. The anterior and lateral branches are visceral in distribution whereas the dorsal branches supply the body wall, vertebral column, vertebral canal and its contents. The ventral branches include the celiac trunk, superior and inferior mesenteric arteries; the dorsal branches are the lumbar and median sacral arteries; the lateral branches are the inferior phrenic, middle suprarenal, renal and gonadal arteries while the terminal branches are the common iliac arteries.<sup>1</sup>

Celiac trunk, Superior mesenteric artery and the Inferior mesenteric artery arise independently from Abdominal Aorta, one above the other at different vertebral levels i.e. T12, L1 & L3 vertebrae

respectively. Several anatomic and radiologic descriptions of variations in the origin of the digestive arteries—celiac artery (CA), superior mesenteric artery (SMA), and inferior mesenteric artery (IMA)—have been reported in the literature.<sup>2</sup> These variations include common trunks and anastomoses between two of the three arteries, such as the celiac-mesenteric trunk between the CA and SMA, or rarer variants, such as the intermesenteric arcade between the SMA and IMA and celiac-bimesenteric trunk.<sup>3</sup> Such anatomic variants have the potential consequence of being stenotic or occluded.

Knowledge of variations is required to avoid complications during surgical interventions involving GIT and posterior abdominal wall including small and large bowel surgeries, laparoscopic surgery, and radiological procedures in the upper abdomen or invasive arterial procedures. Awareness of such variations can result in accurate interpretation of disease and vascular involvement, optimal selection of treatment options or operative planning, and help avoid iatrogenic injury from surgical and interventional radiological procedures.<sup>4</sup>

### MATERIAL AND METHODS

The scans of 70 subjects who had undergone abdominal MDCT angiography examination were retrospectively reviewed.

---

#### *Address for Correspondence :-*

Dr. Garima Sehgal, Deptt. of Anatomy KGMU, Lucknow, U.P.

E-mail: dr.garimabhasin@gmail.com | Mob: 9044513758

Celiacomesenteric Trunk: An Unusual Variation

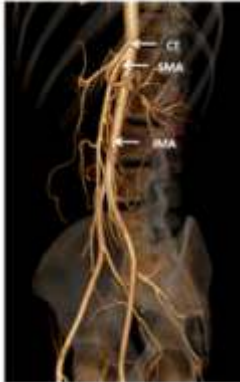

Figure 1: 3D volume rendered image depicting origin of CT (celiac trunk), SMA (superior mesenteric artery) and IMA (inferior mesenteric artery) from the ventral surface of aorta.

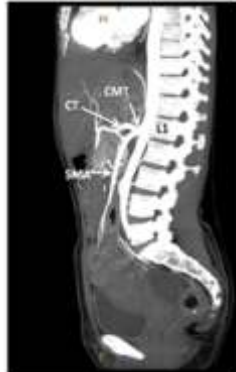

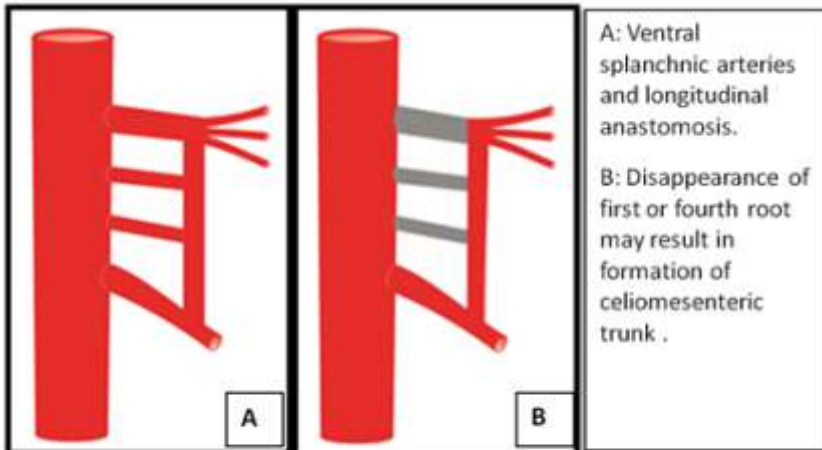
Figure 2: MIP (Maximum intensity projection) image depicting the origin of CMT (celiacomesenteric trunk), CT (celiac trunk), SMA (superior mesenteric artery).

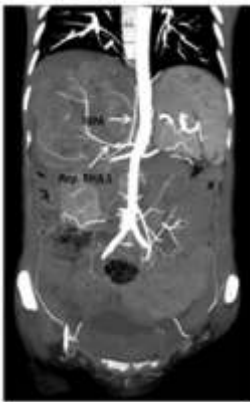

Figure 3: MIP (Maximum intensity projection) image showing Rep. RHA I (first replaced right hepatic artery from aorta) with RIPA (right inferior phrenic artery) as branch.

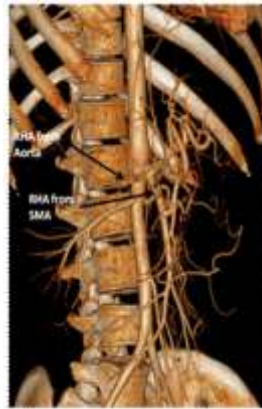

Figure 4: 3D volume rendered image depicting the two replaced right hepatic arteries (RHA).



A: Ventral splanchnic arteries and longitudinal anastomosis.  
 B: Disappearance of first or fourth root may result in formation of celiacomesenteric trunk .

Fig. 5 - Schematic representation of embryologic development of mesenteric arterial vasculature.

**Table:1-** Reported prevalence of celiacomesenteric trunk in different populations.

STUDY	YEAR	POPULATION	STUDY	PERCENTAGE
Ruzicka & Rossi	1968	-	Visceral arteriograms (200 subjects)	0.5%
Mitchels et al.	1995	-	Cadaveric (500 cadavers)	0.25%
Winston et al.	2007	AMERICAN (394 Subjects)	CT Angiography	< 1%
Song YS et al	2010	JAPANESE	CT & DSA	0.10%
Nantiskarn Chanpen, Kiat Arjhansiri	2012	ASIAN (Bankok) (199 Subjects)	MDCT Angiography	3.5%
Anupama D, R.Lakshmi Subhash2	2013	ASIAN(Indian) Case report	Cadaveric	-
Present study	2013	Asian (Indian) 70 Subjects	Multislice CT Angiography	2.85%

The study group included subjects of either gender between the ages 18 month-80 yrs. All the subjects who had undergone previous abdominal surgery or were suffering from any intra abdominal pathology which was likely to distort the anatomy of the region concerned were excluded from our study.

The subjects underwent CT angiography of the abdominal aorta using 64-row CT units. The area from the level of the diaphragm to the iliac bifurcation was scanned. Approximately 100–110 ml of nonionic contrast material (350 mg/ml) was injected with an automatic power injector at a flow rate of 4 mL/s using an 18 G IV line in the antecubital vein. The scan delay was set using automated bolus tracking software to capture 150 HU of the abdominal aorta at the level of the celiac trunk. All images were evaluated in the standard transverse plane.

Both 3-mm and 1-mm thick images

were reconstructed on the 64-slice CT scanner and then transferred to dedicated workstations to build multiplanar reformatted (MPR) and volume rendered images. The images were evaluated using three-dimensional imaging with combined maximum intensity projection (MIP) and volume rendering (VR) techniques.

## OBSERVATIONS AND RESULTS

In 69 subjects out of 70, Celiac trunk (CT), Superior mesenteric (SMA) and Inferior mesenteric arteries (IMA) displayed separate origins from the anterior surface of abdominal aorta (Fig.1). In one female subject aged 40 yrs celiac artery and superior mesenteric artery originated from the anterior surface of aorta as a *common celiacomesenteric trunk (CMT)*. The origin of this common trunk took place behind the pancreas and in front of lower part of L1 vertebra. After a forward course of about

1.3cm the common trunk gave off the CA as its branch and continued as the SMA (Fig.2). *In addition* to this, left and right inferior phrenic arteries which arise normally from the abdominal aorta also displayed a variation in their origin. Also the supply to the right side of liver was through *two replaced Right Hepatic Arteries (RHA's)* (Fig.4).

The celiac trunk gave off four branches which included the left inferior phrenic artery as its first branch, the second branch was the left gastric artery and terminal branches were common hepatic (consisting of the Left hepatic artery & Gastroduodenal artery) and splenic arteries. The branches from the SMA included inferior pancreaticoduodenal artery, jejunal arteries, ileal arteries, ileocolic, right colic and middle colic artery. Right side of liver received arterial supply through replaced RHA's. The *first replaced RHA (Rep. RHA 1)* originated from the right aspect of abdominal aorta in front of the lower border of L1 vertebra and the right inferior phrenic artery (RIPA) was a branch from the first replaced RHA (Fig.3). The *second replaced RHA (Rep. RHA 2)* was a branch from the SMA given off below the pancreas. Both replaced RHA'S traversed the portocaval space to reach the right side of liver.

## DISCUSSION

Blood vessel development occurs by two mechanisms: (1) vasculogenesis and (2) angiogenesis, which are guided by the vascular endothelial growth factor (VEGF) and other growth factors. The major vessels, including the dorsal aorta and cardinal veins, are formed by vasculogenesis. During embryological period, three sets of arteries for the trunk originate from the aorta. The primitive aorta

appears firstly in the embryo and gives segmental branches to the digestive tube (ventral splanchnic arteries, vitelline arteries), to the mesonephric ridge (lateral splanchnic arteries) and to the body wall (somatic arteries); many intersegmental branches supply the somites and their derivatives during the development.<sup>5</sup> The vitelline arteries are initially paired vessels supplying the yolk sac which gradually fuse and form the arteries in the dorsal mesentery of the gut. In the adult they are represented by the celiac, superior mesenteric, and inferior mesenteric arteries. These vessels supply derivatives of the foregut, midgut, and hindgut, respectively. Inferior phrenic arteries may arise separately from the aorta, just above celiac trunk and help to supply the diaphragm.<sup>5</sup>

Celiac and superior mesenteric arteries having a common origin from the aorta account for less than 1% of all abdominal vascular anomalies. The celiacomesenteric trunk is a rare variation with prevalence ranging between 0.1% - 3.5% as reported in previous literatures. The present study found a prevalence of 2.85% which was higher in comparison to the prevalence found in non-Asian subjects whereas it was somewhat comparable to that found in previous studies on Asian subjects (Table: 1).

The present study describes the origin of celiac artery and superior mesenteric artery from the anterior surface of the aorta through a common trunk (celiacomesenteric trunk) in association with other variations. The CA, SMA and IMA develop from the 10th, 13th and 21st or 22nd ventral segmental (vitelline) arteries that supply the yolk sac of the embryo.<sup>6</sup> Embryologically therefore, the occurrence of celiacomesenteric trunk can be explained

by regression of the 10th root and persistence of both the 13th root and the anterior anastomosis (Fig.5). We also observed other accompanying arterial variations as already explained.

The diagnosis of celiacomesenteric trunk has often been reported during autopsy or accidentally during angiography or abdominal computed tomography scanning.<sup>7,8</sup> It is usually asymptomatic but may present with

- nonspecific abdominal pain
- real abdominal angina,
- aneurysms and Median arcuate ligament syndrome resulting in complete avascularisation of a large segment of GIT and consequent ischemia as this single artery is the sole source of vascularisation of supra colic organs.<sup>9,10</sup>
- Thrombosis of the celiacomesenteric trunk can lead to serious gastrointestinal complications including necrosis of the gastro-intestinal tract (from the stomach up to the first third of the transverse colon), ischemia of the liver and spleen infarction.<sup>9</sup> These complications can easily lead to death.

Understanding the anatomic variations of mesenteric circulation is mandatory in various surgical procedures such as liver transplantation and resection, gastrectomy, biliary reconstruction, right hemicolectomy, resection of the transverse colon, pancreaticoduodenectomy, aortic surgery and in patients with pancreatic and hepatobiliary malignancy, where visualization of the surgical field can often be limited especially when there has been prior surgery, local inflammation accompanying a biliary stent or obesity.<sup>11,12</sup>

Knowledge about variations is also important as CMT is associated with an *intrinsic loss of SMA-CT collateral* which is

an important safeguard protecting against mesenteric ischemia, leaving the bowel with one dominant vascular feed which under unfortunate circumstances could be responsible for serious gastrointestinal complications.

Other accompanying variations included replaced double RHA's supplying the right side of liver. It is important to mention that in diagnostic radiology we need an accurate interpretation of such variant vascular anatomy in patients who are about to undergo pancreatoduodenectomy in order to preserve the vessels and avoid fatal hepatic injury during surgery.<sup>13</sup> Accidental ligation of replaced hepatic artery may also result in hepatic necrosis, ischemic biliary injury, or graft injury.<sup>14</sup> Aberrant arterial branches may in addition interfere with interventional radiological procedures and patients with anatomic variations of hepatic arterial system are at high risk for misperfusion during chemotherapy.<sup>15</sup>

## CONCLUSION

We found the celiacomesenteric trunk in association with many other clinically relevant vascular variations. To our knowledge such a combination of variations has not been reported in previous literatures. Knowledge of the presence of these unique combinations of vascular variations may help during planning of surgical intervention and also prevent mistakes due to lack of awareness. This may be particularly important in places where angiography is not done regularly.

## REFERENCES

1. Warwick R, Williams LP. Gray's Anatomy. Susan Stranding et al. Elsevier

## Celiacomesenteric Trunk: An Unusual Variation

- Churchill Livingstone. 39th ed  
2005;p.1118-1120.
- Hazirolan T, Metin Y, Karaosmanoglu AD, Canyigit M, Turkbey B, Oguz BS, et al. Mesenteric arterial variations detected at MDCT angiography of abdominal aorta. *AJR*. 2009; 192:1097-102.
  - Nonent M, Larroche P, Forlodou P, Senecail B: Celiac-bimesenteric trunk: anatomic and radiologic description—case report. *Radiology* 2001, 220:489-491.
  - Yalcin B, Kocabiyik N, Yazar F, Ozan H and Ozdogmas O. Variations of the branches of the celiac trunk. *Gulhane Tip Dergisi*, 2004, p. 183-185.
  - Vascular development in Cardio vascular System. In *Langman's Medical Embryology*. T.W. Saddler. 11 th ed. p185-89.
  - Tandler J. Über die Varietäten der Arteria coeliaca und deren Entwicklung . *Anat Hefte* 1904 ; 25 (2): 473– 500 .
  - Cavdar S, Sehirli U, Pekin B. Celiacomesenteric trunk. *Clin Anat*. 1997;10:231-4.
  - Wang Y, Chen P, Shen N, Yang JT, Chen JH, Zhang WG: Celiomesenteric trunk with concurrent aneurysm: report of a case. *Surg Today* 2010, 40:477-481.
  - Ailawadi G, Cowles RA, Stanley JC, Eliason JL, Williams DM, Colletti LM, Henke PK, Upchurch GR: Common celiacomesenteric trunk: aneurysmal and occlusive disease. *J Vasc Surg* 2004, 40:1040-1043.
  - Loukas M, Pinyard J, Vaid S, Kinsella C, Tariq A, Tubbs RS: Clinical anatomy of celiac artery compression syndrome: a review. *Clin Anat* 2007, 20:612-617.
  - Winston CB, Lee NA, Jarnagin WR, Teitcher J, DeMatteo RP, Fong Y, et al. CT angiography for delineation of celiac and superior mesenteric artery variants in patients undergoing hepatobiliary and pancreatic surgery. *AJR*. 2007; 188:W13-W19.
  - Nicolas Lagoutte, Olivier Facy, Boris Giiu. Celiacomesenteric trunk: a variation that must be known before aortic surgery. *Clinics and Practice* 2011;vol1:69
  - Lee JM, Lee YJ, Kim CW, Moon KM, Kim MW. Clinical implications of an aberrant right hepatic artery in patients undergoing pancreaticoduodenectomy. *World J Surg*. 2009; 33:1727-32.
  - Gruttadauria S, Foglieni CS, Doria C, Luca A, Lauro A, Marino IR. The hepatic artery in liver transplantation and surgery: vascular anomalies in 701 cases. *Clin Transplant*. 2001;15:359-63.
  - Daly JM, Kemeny N, Oderman P, Botet J. Long-term hepatic arterial infusion chemotherapy. Anatomic considerations, operative technique, and treatment morbidity. *Arch Surg* 1984; 119: 936-941