

STUDY OF ARTERIAL PATTERN OF NORMAL PLACENTA BY CORROSION CAST METHOD AND TO CORRELATE IT WITH ITS SURFACE AREA

Shaily Verma*, Shikky Garg*, Vasundhara Kulshreshta*,
Anshu Gupta*, Ved Prakash*, Richa Singh**

*Department of Anatomy, S.N.M.C. Agra

** Department of Obstetrics & Gynaecology, S.N.M.C. Agra

ABSTRACT

The aim of our study is to find out the arterial pattern of normal placenta by corrosion cast method and to correlate arterial pattern with the surface area. Two types of arterial patterns were found – Dispersed and Magestrial. 20 normal placenta were collected from labour room. 70% placenta were of dispersed variety and 30% were of magestrial variety. Maximum and minimum surface area in dispersed variety was 452 and 201 square centimeter. Maximum and minimum surface area in magestrial variety was 333 and 191 square centimeter. Dispersed variety were found in more number of cases. Surface area was greater in dispersed variety than in magestrial type.

Keywords : Placenta, dispersed, magestrial, surface area

INTRODUCTION : Placenta is a mirror which reflects the intrauterine status of foetus.¹

The human placenta is a discoid shaped, highly vascularized organ which develops from the uterus and developing embryo. The fetomaternal blood circulation within the placental vasculature is responsible for producing healthy baby by delivering the required oxygen and nutrients, excreting out waste products along with its endocrinal and detoxification function. It originates at the insertion of 2 umbilical arteries and terminates at umbilical vein. It has 2 surfaces, maternal and foetal which are almost equal in area – as the main arterial branches lie in the horizontal plane while in most other organs of the body they lie in three dimensions.

The insertion of umbilical cord may be centric or eccentric (M. Yampolsky²). Umbilical cord has 2 umbilical arteries and 1 umbilical vein. The 2 umbilical arteries are usually fused together via Hyrtl's anastomosis³ just proximal to umbilical cord insertion (photograph 3). Hyrtl's anastomosis helps in equal distribution of blood and regulation of pressure through placenta. According to Schordania³ arterial pattern may be dispersed (Dichotomous) or magestrial (Monopodial). In dispersed variety each umbilical artery of placenta begins at once a series of division, dichotomous in nature which fills each half of placenta with arteries of gradually diminishing caliber. In magestrial variety, caliber of umbilical artery remains

same as far as the margin of placenta before their caliber diminishes. According to Schordania³, vascular pattern is not a haphazard phenomenon but is genetically determined by vascular characteristic of mother.

MATERIALS & METHOD : 20 normal placenta were collected from the department of Obstetrics and Gynecology, S.N.M.C. & Lady Lyall Hospital, Agra. Exclusion criteria were anemia, hypertension, chronic renal failure in mothers. Placenta immediately washed with water, amniotic membranes were trimmed off, blood clots were removed subchorionic vessels were emptied off blood by applying gentle pressure. Umbilical cord was cut 1 cm from placental surface.

Injection Technique was used to prepare cast – Umbilical arteries were identified, 15 no. needle was inserted into one of them, tied with thread around umbilical cord. Then 15-20 ml of butyl butyrate dye (6% - 6gm dissolved in 100ml acetone) was injected into it. Needle & syringe were taken out and the thread firmly tightened. Same procedure repeated with other artery (Photograph 1).

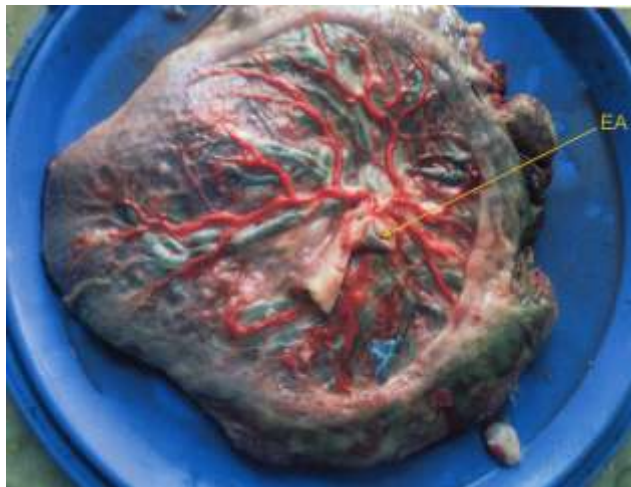Placenta kept flat (with maternal surface underside), on a graph paper. Its outline was marked. Placenta then removed and its surface area was calculated by counting the number of squares (1cm × 1cm) in square centimeter. It is known as Graph Method. (Photograph 2).

Address for Correspondence:

Dr. Shaily Verma

Room No. 2, 15/315, Mahamaya House, Near Noori Gate, Agra

Postal Code : 282002

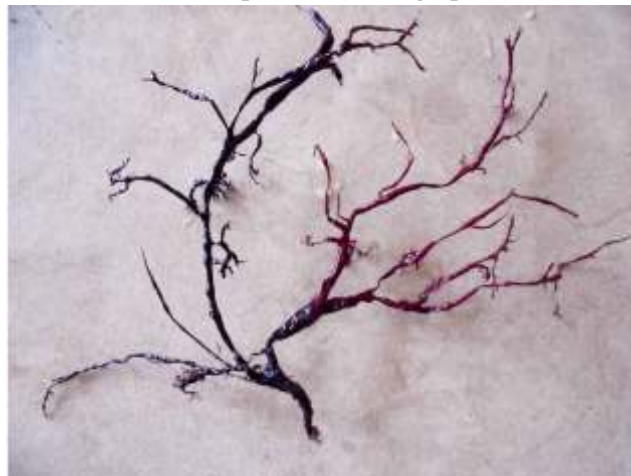

Photograph-1: Injection Technique – Red coloured dye injected in right umbilical artery.



Photograph-2: Graph Method for calculating surface area of placenta

Placenta kept in 10% formaldehyde for 1 day then in 30% KOH for 7 days, casts were then ready and observed for arterial pattern. (Photograph-3)



Photograph-3: Placental cast. Note red coloured dye in right artery. Dark blue in left umbilical artery and Hyrtl's anastomosis between the two arteries (shown by arrow). Photograph also shows mixing of the dye in the proximal part of the right umbilical artery.

OBSERVATIONS : Following observations were made.

**Table – 1
Placental Arterial Pattern**

| S.No. | Pattern | Number | Percentage |
|-------|------------|--------|------------|
| 1. | Dispersed | 14 | 70% |
| 2. | Magestrial | 06 | 30% |

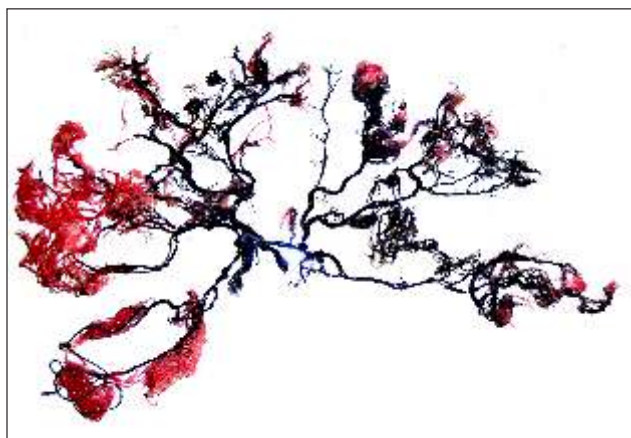
**Table – 2
Mean Surface Area**

| S.No. | Pattern | Mean Area (cm ²) | Maximum Area (cm ²) | Minimum Area (cm ²) |
|-------|------------|------------------------------|---------------------------------|---------------------------------|
| 1. | Dispersed | 326.56 | 452.16 | 200.96 |
| 2. | Magestrial | 262.00 | 333.00 | 191.00 |

RESULTS : We studied the normal pattern by corrosion cast. Out of 20 placenta, we found that 14 placenta i.e. 70% were of dispersed variety (Photograph 4) and 6 placenta i.e. 30% were of Magestrial variety (Photograph 5).



Photograph-4: Dispersed type of arterial pattern



Photograph-5: Magestrial type of arterial pattern

From table 2 it is clear that the mean surface area in dispersed variety was 326.56cm² and that in magestrial variety was 262 cm². Maximum and minimum surface area in dispersed and magestrial variety were 452.16cm² (max.), 200.96cm² (min.), 333 cm²(max.) and 191 cm² (min.) respectively.

DISCUSSION AND CONCLUSION :

We can conclude from our study that are dispersed variety of arterial pattern was more in number than the magestrial variety. Mean surface area was greater in dispersed variety than in magestrial variety. Gross anatomy of placenta like surface area is virtually a description of vascular anatomy. The handy information regarding the normal arterial pattern and surface area is useful for academicians and medical practitioner to interpret the various fetal and maternal data. Study of the arterial pattern help to know the pathophysiology of twin to twin toxic syndrome (TTTS)⁴ and developmental anomalies. Hyrtl's anastomosis regulates blood pressure. This helps to know fetal status in cases of abnormal umbilical artery resistance to blood flow by Doppler ultrasonography.

Study of normal parameter of surface area will help ultrasonologist, gynecologist in prenatal diagnosis of adverse conditions like large placenta having large surface area is associated with blood incompatibilities⁵⁻¹², maternal diabetes, anemia, homozygous thalassemia whereas decreased surface area is associated with fetal distress, Pregnancy Induced Hypertension (PIH), low birth weight babies¹³, congenital and chromosomal anomalies etc.

Placenta is used as a witness¹⁴, so it can be useful for medicolegal purposes for example in case of cerebral palsy. Litigations can be put forward against medical negligence but then the gross examination of

small size of the placenta itself tells that it was the insufficient supply in the utero that was responsible for this and not the medical negligence. Other example can be neonatal death due to severe anemia¹⁵. Here also histomorphological examination of smaller size, smaller weight and lesser volume of placenta which are infact compensatory mechanism to maternal hypoxia defend medical practitioners.

So in cases where the adverse outcome is suspected, placenta must be secured and photographic record must be made of any potential gross pathological finding. Placenta alone may not provide complete answer but it is essential and important witness in understanding adverse outcome.

REFERENCES :

1. Udanie A Bhagwal Distress in PIH with its clinical relevance et al j Ana. Society India (2004)., 53(1): 27-30.
2. M. Yampolsky, C. Salafia, O. Shlakhter, D. Haas, B. Eucker, J. Tharp (2008) Modeling the variability of shapes of a human placenta, Placenta, 29 (2008). 790-797.
3. Schordania J. (1929. Arch. Gynaek. Bd. CLim. 12; 45.
4. Veerabhadrappe HC, Study of the vascular organization of the placenta, international journal of Health Science and Research (2013); 3(4); 32-35.
5. Frieman EA, Sachtleben MR. Influence of placental weight of Labour Obstet Gynecol 1969; 33: 404-408 Medline.
6. Nummi S. Relative weight of the placenta and perinatal mortality : a retrospective clinical and statistical analysis. Acta Obstet & Gynecol Scand Supple 1972; 17: 1-69 Medline.
7. Godfrey KM, Redman CW, Barker DJ, Osmond C. The effect of maternal anaemia and iron deficiency on the ratio of fetal weight to placental weight. Br. J. Obstet Gynaecol 1991; 98: 886-891. Medline.
8. Gichangi PB, Nyong'o AO, Temmerman M. Pregnancy outcome & placental weight : their relationship to HIV-1 infection East Afr Med J 1993; 70: 85-89. Medline.
9. Jauniaux E, Ramsay B, Campbell S, Ultrasonographic investigation of placental morphologic characteristic and size during the second trimesters of Pregnancy. Am. J. Obstet Gynecol 1994; 170 : 130-137. Medline.

10. Ananth CV, Berkowitz GS, Savitz DA Lapinski RH. Placental abruption and adverse perinatal outcome. JAMA 1999; 282 : 1646 – 1651. Gross RefMedline.
11. Lao TT, Tam KF. Placental ratio and anaemia in third trimester pregnancy. J. Reprod Med 2000; 45-923-928 Medline.
12. Faddar GM, D'Antona D. Amkrosini G, et al placental and fetal pulsatility in dices in Gestational DM. J. Reprod Med 2001; 46: 365-370 Medline.
13. Hoogland HJ, delHaam J. Martin CB, Placental size during early pregnancy and fetal outcome, a preliminary report of sequential ultrasound study. AM Journal Obstet Gynaecol 1780; 138: 441-3.
14. Placenta as witness Rebecca N. Baengren, MD clin Prenol 34 (2007) : 393-407.
15. Mongia S, Jain S, Yadav M, Placenta : The Wonder Organ, J. Indian Acad Forensic Med. (2011), Vol. 33; 140-142.