

LATERAL VENTRICLE RATIOS CORRELATED TO DIAMETERS OF CEREBRUM-A STUDY ON CT SCANS OF HEAD

POONAM PATNAIK*, VISHRAM SINGH**, SATBIR SINGH***, DALVINDER SINGH****

*Assistant Professor, Department. of Anatomy, Jamia Millia Islamia, New Delhi, Research scholar at SMC & H. Ghaziabad.

**Professor and Head, Department. of Anatomy, Santosh Medical College, Ghaziabad.

***Director Professor, Dept. of Radiology and Imaging, G.B. Pant Hospital ,New Delhi.

****Associate Professor, Department of Anatomy, , Jamia Millia Islamia, New Delhi

ABSTRACT:

Lateral ventricles of brain are enlarged with normal ageing, neurodegenerative diseases and in hydrocephalus. On Computerized tomography(CT), ratios of the width of ventricles to the width of skull or brain are probably the most easily reproducible ventricular measurements. Therefore, an attempt has been made here to correlate these ratios to the diameters of the cerebrum, as a part of PhD thesis work of 1ST author under the supervision of 2nd , 3rd , and 4th authors with the objective of (1) establishing the range of parameters for lateral ventricles for the diagnosis of mild ventricular dilatation and (2)Correlating these parameters with anteroposterior(AP) and transverse(TD) diameter of cerebrum, if any. A Retrospective study of 60 near normal CT scans-(head) collected from the department of Radiology and Imaging, G.B. Pant Hospital, (patient age 5 to 70 yrs) submitted to morphometric measurements of ventricles by Dicom Image software and data evaluation. Using axial views of cerebral hemispheres, Frontal Horn Ratio (FHR), Bicaudate Ratio(BCR), Evan's Ratio(ER), Bifrontal Index, Bioccipital Index and Cella Media Ratio (CMR) were calculated and correlated to AP and TD of cerebrum using Pearson's correlation coefficient. Mean FHR, BCR and ER were found to be 0.30 ± 0.04 , 0.12 ± 0.03 and 0.27 ± 0.035 respectively. Correlation coefficient (r) between FHR and AP, TD was found to be -0.11 and -0.01 respectively. Mean cella media ratio was 0.22 ± 0.04 . Correlation coefficient between CMR and AP, TD was 0.38 and 0.27 respectively. Bifrontal Index and Bioccipital Index were 0.29 ± 0.04 and 0.42 ± 0.05 with r being 0.25 (AP), 0.27 (TD) and 0.13 (AP), 0.03 (TD) respectively. Conclusively, there is very mild negative correlation between FHR and AP whereas none with TD. Maximum correlation was between CMR and AP whereas negligible between Bioccipital ratio and TD.

Key Words: Lateral ventricle ratios, Cerebrum diameters.

INTRODUCTION

Morphometric analysis of brain ventricles is important for evaluating changes due to growth, ageing, intrinsic and extrinsic pathologies¹. Blockage of cerebral aqueduct is a common cause of hydrocephalus causing high pressure in lateral ventricles leading to extremely serious condition due to both, the damage caused by the pressure as well as the nature of lesion that caused the block (e.g. a tumor or inflammatory swelling). Morphometric study of ventricles is helpful in the diagnosis and classification of hydrocephalus as well as in assessment and follow up of enlargement of ventricular system during therapy (ventricular shunts)². Therefore a baseline data is must for comparison and early detection and diagnosis of mild hydrocephalus and followup thereafter.

Though MRI has evolved as the new technique yet visualization of brain ventricles by CT remains the most widely available and relatively affordable tool in Indian scenario. Brain ventricles can be studied by taking linear, planimetric or volumetric measurements, out of which, linear ratios of the width of ventricles to the width of skull or brain are probably

the most easily made and reproducible ventricular measurements. The linear measurements of the lateral ventricles bear a positive correlation to cranial size³. In the past, linear lateral ventricular parameters have been correlated to ventricular volumes⁴, but none of the studies are available where linear lateral ventricular ratios have been correlated to linear dimensions of cerebrum.

By CT, temporal horns cannot be identified with certainty and clear delineation of the temporal horns implies that they are dilated⁵. The diagnosis of hydrostatic hydrocephalus is probable when there is visualization of temporal horn tips measuring 2 mm or more in width and the lateral ventricles are symmetrically enlarged with Frontal horn ratio 0.50 or more⁶. In patients with Normal pressure hydrocephalus, certain parameters of lateral ventricular size including Evan's ratio (ER) and Cella media width (CMR) get reduced to normal after ventriculoperitoneal shunt operation⁷. Ventricular measurements are also important in alcoholics and in dementia patients. Dementia patients with little atrophy by brain CT showed better prognosis⁸. Ventricular size

Address for Correspondence:

Dr. Poonam Patnaik , Assistant Professor, Department of Anatomy, Jamia Millia Islamia, New Delhi.

Email id: drpoonam.patnaik@gmail.com

Mobile: 09971078760

increases faster in alcoholics (11% per year) than in controls (2% per year)⁹.

Therefore generating baseline data for these parameters and correlating them with cerebrum dimensions can be of much use in a wide variety of clinical practice.

MATERIAL AND METHODS

This is a retrospective, cross-sectional, non-interventional study. The study group was drawn from patients reporting to the Department of Radiology and Imaging, G.B Pant Hospital, for head CT examination for various indications during Feb-March 2014. Institutional ethical committee clearance was duly obtained and the study was conducted in Department of Anatomy, Santosh Medical College and Hospital in collaboration with Jamia Millia Islamia, Central University at Delhi.

60 virtually normal head CT scans without changes (as reported by Radiologists) were collected on DVD. Patients of both sex and age group 5-70 years were included in the study. CT scans showing gross pathological changes affecting the normal anatomy of ventricles (e.g. due to large metastasis etc.) were excluded from the study group.

METHODOLOGY All CT scans were taken by trained and experienced radiographer in standardized condition and manner. CT study of brain was done in axial transverse scanning on the multi slice CT scanner.

The scans were obtained on a plane at an angle of 15 degree to and 1 cm above the infra-orbitomeatal line. All other technical parameters. (time in ms, potential in kv, current in mA) of the scans were as per the established standards with slice thickness of 8 mm.

CT scans were selected out of the routinely done investigations. No extra scans were indicated for the purpose of study, to avoid unnecessary radiation exposure.

The linear measurements were taken in CT images as per table I with the help of Dicom Image Software. The parameters were calculated and analyzed as per Table-II.

OBSERVATION AND RESULTS

Mean 'a', 'b', 'c', were 29.86 mm, 32.68mm and 13.14mm respectively. Mean of 'A', 'D', 'C' were 99.53 mm, 120.90 mm and 108.4mm respectively. Mean antero-posterior diameter of cerebrum was 155.40 mm and Transverse diameter was 118.69 mm for studied group.

All parameters of lateral ventricle ratios, Pearson's Correlation coefficient (r) and Spearman's rank correlation coefficients (rs) with Antero-posterior and Transverse diameter of Cerebrum have been shown in Table II.

Figures 1 to 8 depict the graphical representation of correlation of these parameters to AP and TD.

DISCUSSION

Mean Frontal horn ratio was found to be 0.30, similar as in the studies by Hahn and Rim¹⁰ (1976) on 200 normal CT scans (0.31). It showed very mild nonsignificant (p=0.4) negative correlation with anteroposterior and transverse diameters of cerebrum (Fig 1 and 2).

The upper limit of Bicaudate ratio was found to be 0.21 as reported (0.2) by Pellici¹¹ (1979). BCR showed mild, almost equal correlation with AP (r=0.27) and TD (r=0.25) (Fig.3).

Bi-caudate ratio and frontal horn ratio have been used in earlier studies to investigate "atrophy of the caudate nuclei in patients with Huntington's chorea and cerebral atrophy".

Doraiswamy et al (1995)^{11a} in their study on 49 normal volunteers, without any significant neurological or psychiatric disorder, reported positive correlation of age to Bi-caudate ratio and Frontal horn ratio.

Evan's ratio was 0.27 +/- 0.035 corresponding to the finding of Gawler⁵ and Synek¹² ((1976), according to whom it was 0.29 or lower. It showed significant correlation with AP (P=.019) and weak non-significant correlation with TD (Fig.4).

Hang¹³ (1977) reported CMR to be 0.295 (age 61—71) increasing gradually with age. In our finding, it was 0.22 which is due to wider age group in our study. Cella media ratio showed maximum correlation (Fig 5 and 6) with AP and TD amongst all ratios which suggest that with increase in size of cerebrum, CMR also increases. The correlation was statistically most significant (p=0.004) with AP (Table III) as compared with other parameters.

Bi-frontal index, as mentioned in the international literature, is a reliable index of size of ventricular system because it is easily reproducible than indicator of width of ventricular bodies⁶. It is the quotient of maximum distance of most lateral borders of frontal horns to internal diameter of the skull in the same line. In our study Bi-frontal index showed almost equal, non-significant correlation with AP and TD. (Fig 7).

Frontal horn ratio, which is the ratio of distance between the tips of frontal horns to internal diameter of the skull in the same line, shows negative correlation whereas bi frontal index shows positive correlation with the diameters of cerebrum, which suggests that with increase in AP and TD, frontal horns of lateral ventricles dilate laterally more than anteriorly.

Bi-occipital index was found to have mild correlation with AP whereas none with TD($r=0.03$), (Fig 8).

Almost similar r and r_s values (table-II) indicate no prominent outliers, data being elliptically

distributed in the scatter diagrams .(Fig1 to 8) . Ratio disturbances could also be used to grade disease, plan treatment and further follow up.

CONCLUSIONS

FHR showed negative correlation with antero-posterior and transverse diameters of cerebrum whereas all other ratios showed positive correlation. CMR depends upon cerebrum size and bi-occipital index does not depend upon dimensions of cerebrum.

The detailed ranges of parameters of table II, can be useful in determining the deviations in borderline cases, where other signs are murky.

Table: I Image selection and linear measurements taken

<p>Image [A1] & [A2] At the level of head of caudate nucleus</p>	<p>Distance between the tip of frontal horns = (a) Inner diameter of the skull in the same line as, (a) = (A) Widest distance between the lateral walls of frontal horns = (b) Minimum distance between the caudate indentations of frontal horns = (c) Inner diameter of the skull in the same line as c = (c) Widest inner diameter of the skull = (D) Antero-posterior diameter of Cerebrum (AP) in the midline Transverse diameter (TD) of cerebrum, perpendicular to AP, at its midpoint</p>
<p>Image [B] At the level of Cella Media</p>	<p>CM1 : Narrowest width between the lateral walls of lateral ventricles CM2: internal diameter of the skull in the same line as CM1</p>
<p>Image [C] At the level, above the caudate nucleus, where ventricular system is widest</p>	<p>Widest distance between lateral borders of frontal horns = [D1] Internal diameter of the skull in the same line as D1 = [D2] Widest distance between lateral borders of occipital horns = [D3] Inner diameter of the skull in the same line as D3 = [D4]</p>

Table: II. Values of all parameters of lateral ventricles and Pearson's Correlation coefficient with Anteroposterior and Transverse diameter of Cerebrum

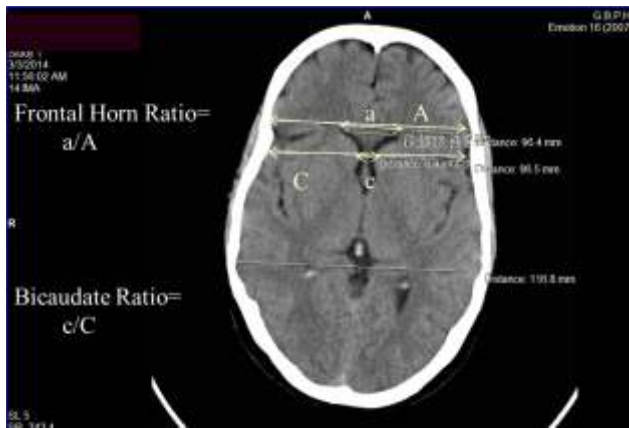
Parameters	Mean	S.D.	Range		CC (r) with		r _s with AP	r _s with TD
			Min	Max	AP	TD		
Frontal Horn Ratio (FHR)=a/A , n=60	0.30	+/-0.04	0.17	0.50	-0.11	-0.01	0.04	-0.02
Bicaudate Ratio (BCR)=c/C , n=60	0.12	+/-0.03	0.05	0.21	0.27	0.25	0.32	0.30
Evan's Ratio (ER)=b/D , n=60	0.27	+/-0.035	0.14	0.34	0.30	0.17	0.34	0.15
Cella Media Ratio* (CMR)=CM1/CM2	0.22	+/-0.04	0.15	0.32	0.38	0.27	0.30	0.16
Bi-frontal Index D1/D2 ; n=49	0.29	+/-0.04	0.21	0.40	0.25	0.27	0.31	0.21
Bi-occipital Index D3/D4 ; n=49	0.42	+/- 0.05	0.32	0.54	0.13	0.03	0.12	0.01

(*for CMR, n=54) ; S.D.(Standard deviation) ; CC: Pearson's correlation coefficient ; rs : Spearman's rank correlation coefficient.

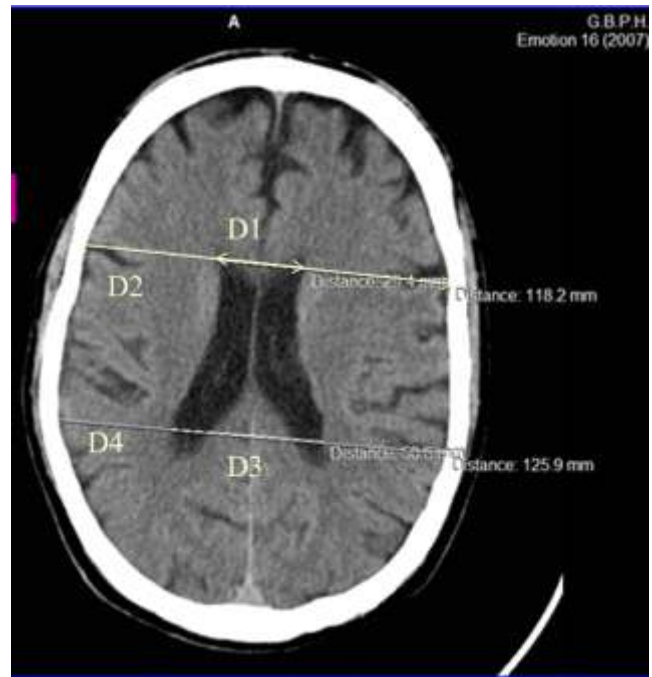
Table III p values of correlation coefficient (as per Statistics Calculators versions 3.0)

Parameter	p value with AP	Significance level	p value with TD	Significance level
FHR	0.40	NS	0.93	NS
BCR	0.036	S	0.054	NS
ER	0.0198	S	0.194	NS
CMR	0.004	S	0.048	S
Bi-frontal index	0.083	NS	0.060	NS
Bi-occipital index	0.37	NS	0.837	NS

S: Significant; NS: Non-Significant



Image[A1] at the level of head of caudate nucleus



Image[C]: at the level, above the caudate nucleus. (Where ventricular system is widest.)

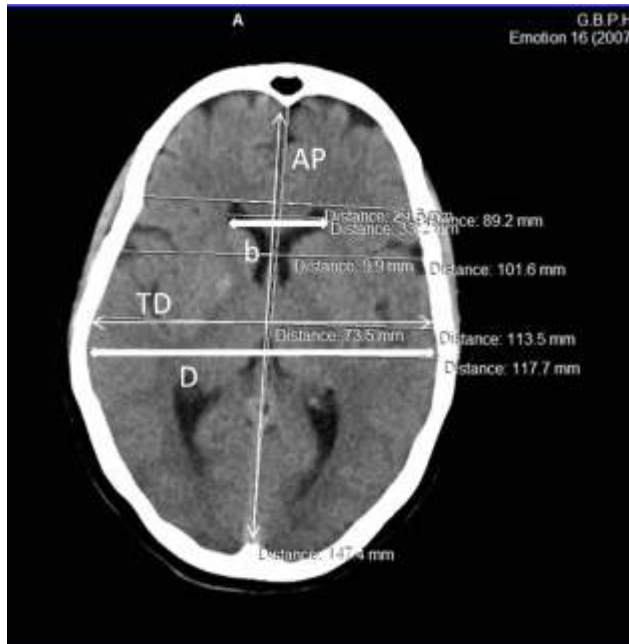


Image [A2] : At the level of head of caudate nucleus , Evans' ratio = b/D .

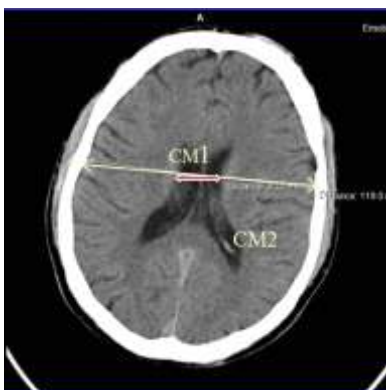


Image [B] at the level of Cella media. (Central part of lateral ventricle)

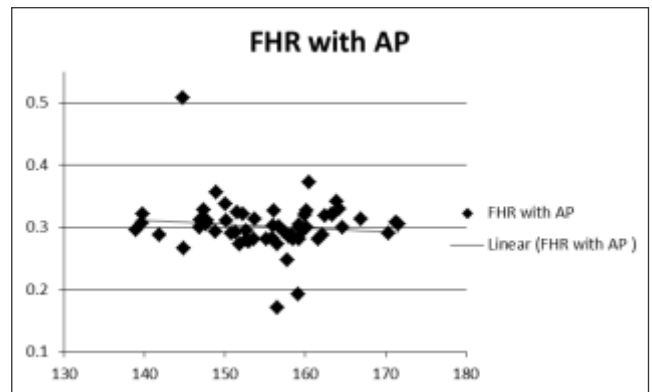


Fig.1- Frontal horn ratio correlated to AP

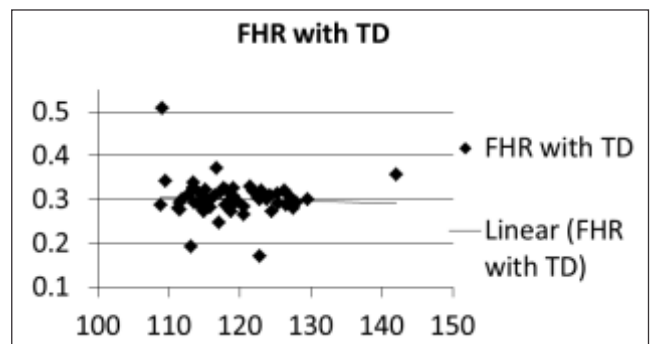


Fig.2- Frontal Horn Ratio Correlated to TD

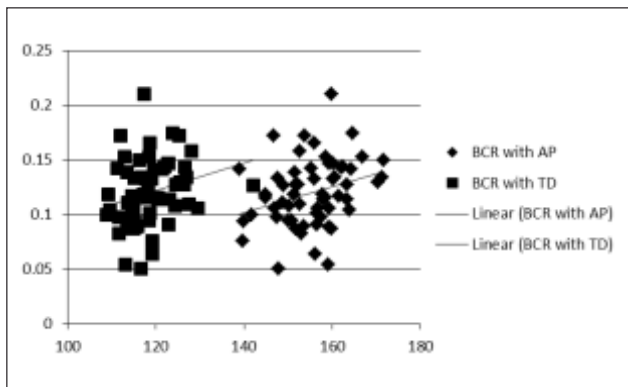


Fig 3- Bicaudate Ratio correlated to AP and TD

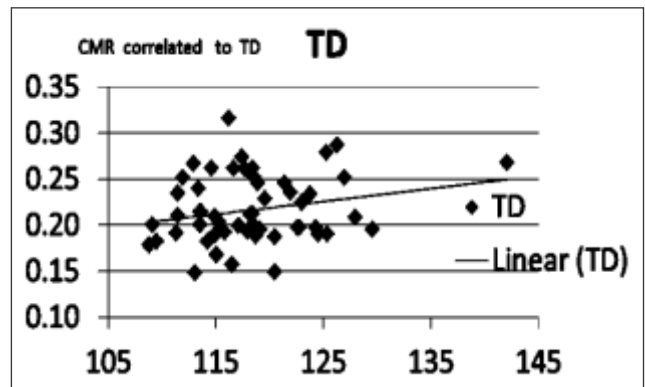


Fig.6- Cella Media Ratio correlated to TD.

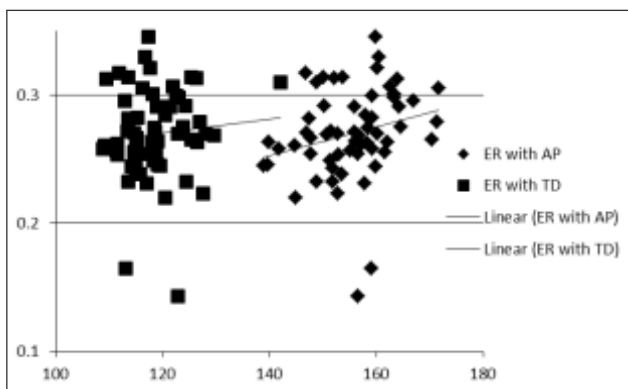


Fig.4- Evan's Ratio Correlated to AP and TD

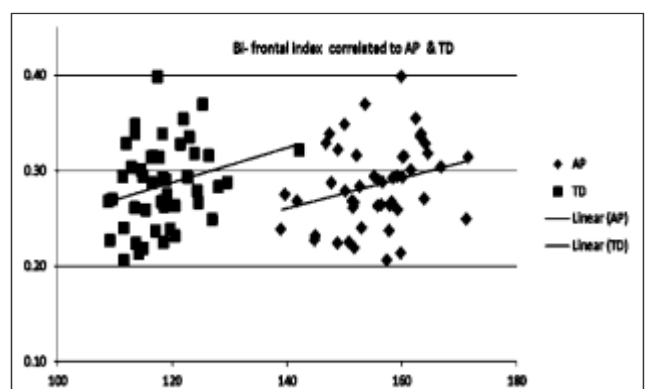


Fig. 7- Bi-frontal index correlated to AP and TD.

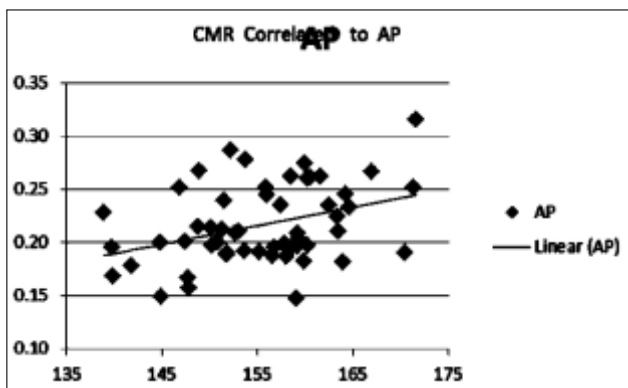


Fig.5- Cella Media Ratio Correlated to AP

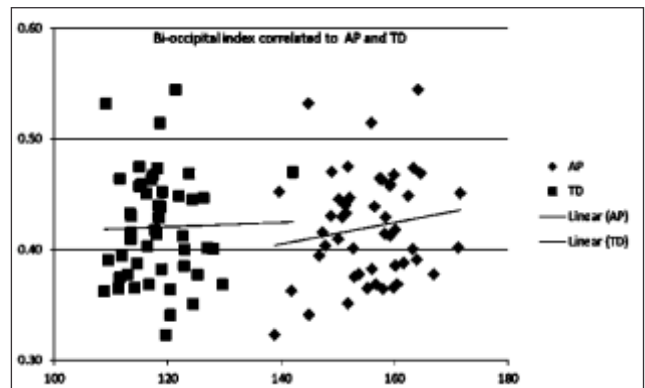


Fig. 8- Bi-occipital index correlated to AP and TD.

REFERENCES:

1. Aziz ,Aamer, Hu, Qing M, Nowinski, Wieslaw L, Morphometric analysis of cerebroventricular system from MR images. Med Image 2004; 5369; 574-82
2. Losowska-Kaniewska D, Oles A. Imaging Examinations in children with hydrocephalus. Adv.Med.Science 2007; 52(1): 176-9

3. C. Gyldensted, Measurements of the normal ventricular system and hemispheric sulci of 100 adults with computed tomography: Neuroradiology, 1977, Volume 14, Issue 4, 183-192
4. O'Hayon BB, Drake JM, Ossip MG, Tuli S, Clarke M., Frontal and occipital horn ratio: A linear estimate of ventricular size for multiple imaging modalities in pediatric hydrocephalus. Pediatr

- Neurosurg. 1998 Nov; 29(5):245-9.
5. Gawler J, DuBoulay GH, Bull JHD, Marshall J, Computerized Tomography: a comparison with pneumoencephalography and ventriculography. *J Neurology, Neurosurgery, Psychiatry.* 1976; 39: 203-211
 6. M. Le May, F. H. Hochberg , Ventricular differences between hydrostatic hydrocephalus and hydrocephalus ex vacuo by computed tomography, *Neuroradiology* ,1979, Volume 17, Issue 4, pp 191-195
 7. Wikkelsö C, Andersson H, Blomstrand C, Matousek M, Svendsen P, Computed tomography of the brain in the diagnosis and prognosis in normal pressure hydrocephalus, *Neuroradiology.* 1989; 31(2):160-5
 8. Jacob H Fox, Jodan L Topel, Michael S Huckman. Use of computerized tomography in senile dementia. *Journal of Neurology, Neurosurgery and Psychiatry* 1975; 38: 948-53.
 9. Rohlfing T, Sullivan EV, Pfefferbaum A. Deformation based brain morphometry to track the course of alcoholism: differences between intrasubject and intersubject analysis. *Psychiatry Res* 2006 Mar 31; 146(2): 157-70
 10. Hahn FJY, Rim K, Frontal ventricular dimensions on normal computed tomography. *AJR* 1976; 126:492-496
 11. Pellici LJ, Bedrick AD, Crose RP, Vannucci RC. Frontal ventricular dimensions of the brain in infants and children. *Arch Neurolog.* 1979; 35: 852-853
 - 11a Doraiswamy PM1, Patterson L, Na C, Husain MM, Boyko O, McDonald WM, Krishnan KR. Bicaudate index on magnetic resonance imaging: effects of normal aging: *J Geriatr Psychiatry Neurol.* 1994 Jan-Mar; 7(1):13-7.
 12. Synek V, Tuben JR, DuBoulay GH. Comparing Evans' Index and computerized axial tomography in assessing relationship of ventricular size to brain size. *Neurology (NY)* 1976; 26: 231-233
 13. Haug G. Age and sex dependence of the size of normal ventricles on computed tomography. *Neuroradiology;* 1977; 14: 201-204